


PATIENT

Tucker Cook

PRESENTING CLINICAL SIGNS

 History: Recheck echo. Progressive heart murmur, now grade 4/6. Asymptomatic.
 -Pertinent previous echo findings (11/2021 MML): Mild MR, mild LAE, trace TR. LA: 1.5, LV: 2.7.

SPECIES

Canine

ECHOCARDIOGRAM FINDINGS

2D, m-mode, color flow and doppler imaging is available. Mild diffuse thickening of mitral valve leaflets with no prolapse into the left atrial lumen. Moderate eccentric mitral regurgitation with mild left atrial dilation. Elevated MR velocity. Normal LV diameter with adequate myocardial function. The tricuspid valve appears normal with trace tricuspid regurgitation. Normal right atrial and ventricular diameter and morphology indicating no overt evidence of pulmonary arterial hypertension. The pulmonic and aortic valves are normal in morphology and mobility. Normal pulmonic and aortic outflow velocities with laminar flow. No obvious aortic or pulmonic insufficiency. No pericardial or pleural effusion noted. No obvious cardiac masses.

BREED

Chihuahua

SEX

Male Neutered

AGE

10 years

CARDIAC CHART
WEIGHT

10.6lbs

CANINE CARDIAC PARAMETERS	MR VMAX (m/s)	TR VMAX (m/s)	LA/AO (Boon method)	LA/AO (Heart Base; Swe)	FS (%)	EF (%)	EPSS (cm)
NORMAL PARAMETER	4.5-5.5	<2.7	1.3	<1.6	28-40	40-100	<0.6
PATIENT	6.5		1.2	1.5	45	79	NM
CANINE CARDIAC PARAMETERS	HR (BPM)	AV VMAX (m/s)	PV MAX (m/s)	BODY WEIGHT (kg)	LA 2D short axis Base view (cm)	LVIDd Avg; 2D and m-mode short axis (cm)	LVIDs Avg; 2D and m-mode short axis (cm)
NORMAL PARAMETER	50-100	0.7-1.7	0.7-1.6	BELOW	BELOW	BELOW	BELOW
PATIENT	162	0.97	1.0	4.8	1.5	2.7	1.3
*Normal chamber parameters expressed as a mean value (SD)				3	1.27 (5.3)	2.46 (2.46)	1.36 (5.5)
BODY WEIGHT DEPENDENT PARAMETERS				5	1.40 (4.5)	2.74 (5.2)	1.60 (4.7)
<i>*Note: All measurements based upon multi-modal images and methods. An average value is reported.</i>				10	1.50 (3.8)	3.27 (3.5)	2.06 (3.1)
				15	1.83 (2.0)	3.71 (2.4)	2.43 (2.1)
				20	2.02 (1.9)	4.14 (2.2)	2.80 (2.0)
				25	2.18 (2.4)	4.48 (2.9)	3.10 (2.5)
				30	2.33 (3.3)	4.83 (3.9)	3.39 (3.4)
				35	2.48 (4.3)	5.17 (5.0)	3.69 (4.5)
				40	2.62 (5.2)	5.48 (6.1)	3.96 (5.4)
				50	2.88 (7.1)	6.07 (8.3)	4.46 (7.4)

INTERPRETED BY

 Maggie Machen Lamy,
 DVM DACVIM
 (Cardiology)

IMAGING PERFORMED BY

Kelly Reschny, RVT

HOSPITAL NAME

 New Hamburg
 Veterinary Clinic

REFERRING VET

NP

INVOICE

31979

DATE

7/28/23

INTERPRETATION OF THE FINDINGS & FURTHER RECOMMENDATIONS

Compared to the prior study, findings are remarkably stable. Despite an increase in quantitative MR to likely explain an increase in murmur intensity, the left heart dimensions are stable. An elevated MR velocity is noted, and a baseline BP is recommended. Trace TR is unchanged, and no additional issues have developed.

Given these findings, no cardiac medications are indicated. Given what appears to be slowly progressive disease, prognosis is open (stage B1). Omega fatty acid



PATIENT

Tucker Cook

supplementation and mild salt restriction may be of some long-term benefit. Monitor for development of a cough, labored breathing, exercise intolerance or collapse episodes.

SPECIES

Canine

Anesthetic risk is considered mild if needed. Cardiac protective drug choices (opioid/benzodiazepine premedication, propofol or alfaxalone induction, isoflurane gas) are recommended. Pre-oxygenate for 5-10 minutes prior to induction. Monitor for arrhythmias, hypotension, and hypoxia both intra and post-operatively and intervene as necessary. Mild IV fluid restriction is recommended to avoid fluid overload. Avoid heart rate stimulating drugs such as atropine unless clinically indicated.

BREED

Chihuahua

Recommend conservative monitoring with a recheck echocardiogram in 1 year, sooner if clinical signs arise.

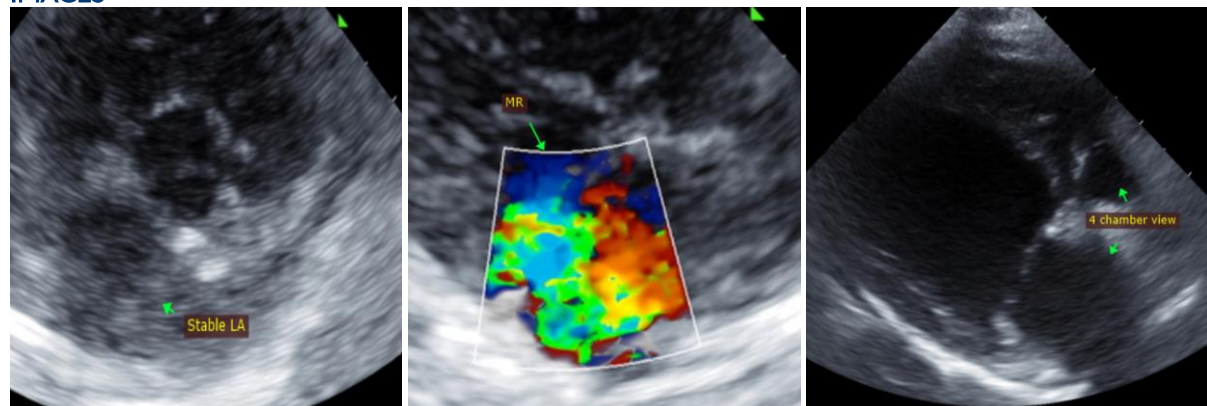
SEX

Male Neutered

IMAGES

AGE

10 years



WEIGHT

10.6lbs

INTERPRETED BY

Maggie Machen Lamy,
DVM DACVIM
(Cardiology)

The information and recommendations provided are based on the images presented by the referring veterinarian. No evaluation can be communicated regarding pathology that was not visible in the image/video clips provided.

IMAGING PERFORMED BY

Kelly Reschny, RVT

Thank you for this referral. This report was generated using transcription software, and minor dictation errors may be present. If the clinical or image interpretation does not parallel your findings or if I can be of any further assistance, please contact me.

HOSPITAL NAME

New Hamburg
Veterinary Clinic

Maggie Machen Lamy, DVM
Diplomate of the American College of Veterinary Internal Medicine (Cardiology)
info@sonopath.com

REFERRING VET

NP

INVOICE

31979

DATE

7/28/23